CLINICAL ORTHOPAEDICS AND RELATED RESEARCH
Number 334, pp 316–325
© 1997 Lippincott–Raven Publishers

Particulate Bioglass Compared With Hydroxyapatite as a Bone Graft Substitute

Hironobu Oonishi, MD, PhD; Shoichi Kushitani, MD*; Eiichi Yasukawa, MD*; Hiroyoshi Iwaki, MD*; Larry L. Hench, PhD**; June Wilson, PhD†; Eiji Tsuji, PhD††; and Tomihito Sugihara, PhD‡*

Bioactive ceramics, notably hydroxyapatite, have been used clinically in various situations in which bone augmentation and restoration are required. Particulate material has been used either alone or in conjunction with freeze dried or autologous bone, with variable clinical success. In this study a bioactive glass, 45S5 Bioglass, has been compared with hydroxyapatite in an animal model to discover whether the 2 major disadvantages of hydroxyapatite may be overcome. These are the difficulty of placing and retaining the particulate in the defect and the length of time needed before full bony restoration is achieved. Bioglass is shown to be easy to manipulate and hemostatic and allows full restoration of bone in 2 weeks, rather than the 12 weeks needed for the particulate hydroxyapatite to produce a comparable response. The Bioglass particulate is used up in the process, and any problems that may be associated with the production of a composite of bone and biomaterial are avoided in the fully restored bone. In any procedure that requires bony augmentation, this rapid response to Bioglass is expected to provide a clinical advantage.

From the *Department of Orthopaedic Surgery, Artificial Joint Section and Biomaterial Research Laboratory, Osaka-Minami National Hospital, Kido-Cho, Kawachinagano-Shi, Osaka, Japan; **Department of Materials Science and Engineering, University of Florida, Gainesville, Florida; †Bioglass Research Center, University of Florida, Gainesville, Florida; ††Osaka Prefectural Industrial Engineering Research Institute, Enokoshima, Nishi-ku, Osaka Japan; and ‡Nitta Gelatin Inc, Research and Laboratory Center 2-22, Futamata, Yao, Osaka, Japan.

Work performed at Department of Orthopaedic Surgery Biomaterial Research Laboratory, Osaka-Minami National Hospital, Osaka, Japan.

Reprint requests to Larry L. Hench, PhD, Department of Materials Science and Engineering, University of Florida, PO Box 116400, Gainesville, FL 32611-6400.

Received: May 19, 1995.

Revised: September 8, 1995; December 7, 1995; February 29, 1996; March 27, 1996.

Accepted: April 8, 1996.

Bone grafts commonly are required in orthopaedic surgery for treatment of nonunions or delayed unions, filling of bone cavities, and replacement of bone lost during tumor removal or trauma.[1–3,6,14] Osseous defects may be left by degeneration cysts in primary surgery for hip and knee arthroplasty and by lysis and resorption of bone revision surgery.[3,14] Autogenous bone currently is regarded as the optimal material for repair of such bony defects.[1–3,14] However, the osteogenic advantage of an autograft often is offset by the limited supply of such bone and the morbidity associated with the surgery to harvest the graft. Thus, there is need for an

allograft material that functions similarly to autograft.

Many calcium phosphate ceramics, such as tricalcium phosphate and synthetic hydroxyapatite, have been tested as bone graft substitutes with generally favorable results because of their osteoconductive characteristics.[2,3,9,11,14] The addition of osteoinductive bone growth factors, such as bone morphogenetic protein, to allografts also has been tested to enhance the rate of bone replacement.[2,3,14]

Previous studies in the authors' laboratory using a rabbit femoral defect model compared the bone response with various calcium phosphate based bioactive ceramics and a nonbioactive ceramic (Al_2O_3).[11,12] The materials studied were synthetic hydroxyapatite, α tricalcium phosphate, β tricalcium phosphate, tetra calcium phosphate, and octa calcium phosphate.[10,11,12] The results showed that there was little new bone formation between Al_2O_3 particles, but at 3 weeks, trabecular bone had formed in the spaces between many of the hydroxyapatite particles.[12] At 3 weeks new trabecular bone also was found between tricalcium phosphate particles, but the particles were dissolving.[12]

The objective of the current experiment is to examine, in the same rabbit model,[10,12] the bone graft characteristics of a highly bioactive glass particulate, 45S5 Bioglass (University of Florida, Gainesville, FL).[4] This material has been in clinical use for a decade in the form of bulk implants for replacement of part or all of the ossicular chain[8,17] and for maintenance of the alveolar bone in edentulous patients.[13] High success rates (90% for a period of 7–10 years), are attributed to a combination of rapid bonding to bone, bonding to soft connective tissues, and a thick, bonding, gel layer that minimizes interfacial stress gradients between implant and tissue.[16,18]

During the last few years the particulate form of 45S5 Bioglass has been tested in the monkey for repair of periodontal defects[18,19] and in the dog for bone graft and rib augmentation.[20] Particulate Bioglass now is used clinically for filling periodontal defects (Perioglas, U.S. Biomaterials Corp., Alachua, FL).[15] These studies showed rapid filling of bony defects. In the case of the canine rib study, the rate of bone repair was greater than that of an equivalent amount of autograft material.[20] It has been hypothesized[5] that this osteogenic behavior of the bioactive glass is attributable to activation of an autocrine response of osteoblast stem cells caused by the controlled release of soluble silicon from the glass surface, as demonstrated in culture by Keeting et al.[7] It is proposed[5] that the soluble silicon activated stem cells produce transforming growth factor β, which is reversibly adsorbed and desorbed in the hydrated silica calcium phosphate gel layer found on the glass. The transforming growth factor β stimulates differentiation and subsequent growth of stem cells, leading to rapid proliferation of bone in contact with the bioactive glass particles. The hypothesis that bioactive glass particulate can increase the rate of bone proliferation compared with that of hydroxyapatite allograft is tested in this experiment.

MATERIALS AND METHODS

Synthetic hydroxyapatite was prepared by sintering at 1200° C in air, as described previously,[12] then crushed into granules and sieved to produce particles of 100 to 300 μm diameter.

Bioactive glass, 45S5 Bioglass, of the following composition (45% SiO_2, 24.5% Na_2O, 24.5% CaO, 6% P_2O_5, all in weight percent)[4] was prepared by melting reagent grade chemicals at 1325° C in a covered platinum rhodium crucible, homogenized for 24 hours, cast, crushed, and sieved to 100- to 300-μm particles.

Model

Holes 6 mm in diameter were drilled bilaterally in the femoral condyles of mature rabbits, and sufficient hemostasis was achieved by filling and compressing the holes with gauze for 5 minutes.[10,12] Immediately afterward, granules of Bioglass and hydroxyapatite were placed in suffi-

cient amounts to fill the holes in the femoral condyles, 1 material on each side, providing each with its own control. Three rabbits were used at each time period.

The animals were euthanized at intervals. Nondecalcified specimens were observed by light microscopic study and backscattered scanning electron microscope imaging, and decalcified specimens were observed by light microscopic study.

The appearance of new bony tissue was identified from the light micrographs and the back scattered scanning electron microscope images. The distance of growth of the new bone from the periphery of the defect was measured in terms of numbers of layers of particles (Fig 1), each layer being nominally 0.2 to 0.3 mm thick (see diagram). The extent of bone surrounding the particles also was assessed from the micrographs and is reported as the time required for bone to surround all of the particles in a layer: that is, to fill all of the space between particles.

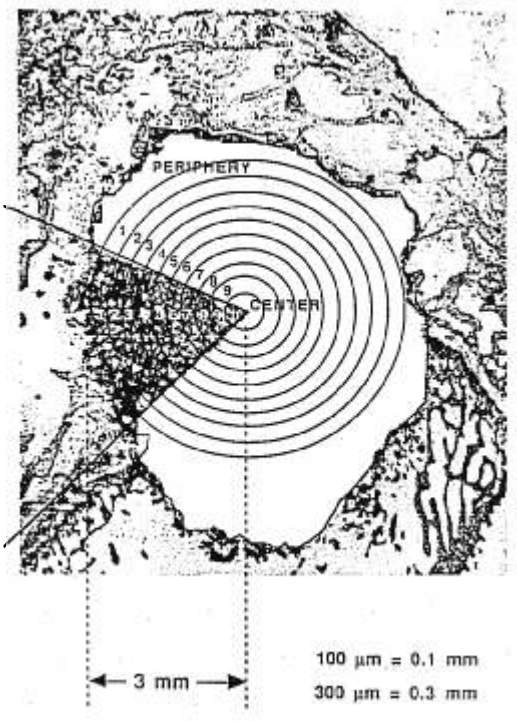

Fig 1. Schematic of the femoral defect, divided into 10 layers of particles from the periphery to the center.

RESULTS

1 Week After Implantation

Figure 2 shows the extent of new bone formation within the Bioglass bone reaction layers. New bone is present at the surface of the Bioglass particle layers to the center of the defect. Interparticle spaces are filled by new bone trabeculae to a depth of at least 4 particle layers. The new bone has a trabecular architecture that incorporates the glass particles within the structure.

A similar trabecular architecture is beginning to form between the hydroxyapatite particles by 7 days but only to a depth of 1 to 2 particle layers. Few hydroxyapatite particles are surrounded by bone at 7 days, although trabecular bridges have been formed between some particles (Fig 3).



Fig 2. The response to Bioglass after 1 week. Bar = 100 µm. Backscattered scanning electron microscope image showing new bony tissue surrounding and connecting Bioglass particles within the defect. The reaction layer and silica rich core can be seen on the particles.



Fig 3. The response to hydroxyapatite after 1 week. Bar = 100 μm. Backscattered scanning electron microscope image showing small amounts of new bony tissue associated with the outermost layer of particles.

2 Weeks After Implantation

The differences in the extent of bone formation between Bioglass particulate and hydroxyapatite granules after 2 weeks' implantation is great. New bone has formed around nearly all of the Bioglass particles and extends to the center of the defect. Glass particles in the periphery of the defect (to layer 5) are joined in the architecture of the trabecular bone. The particles are still whole, although the reaction layer extends into them to a considerable depth.

Bioglass particles in the center of the defect (layers 6–10) also are extensively surrounded by new bone; however, some bridges are incomplete.

By 2 weeks new bone has formed to a depth of 5 to 6 layers on hydroxyapatite particles but surrounds the particles to form a trabecular architecture only to the first 2 to 4 layers. At the center of the defect new bone is just beginning to appear along with some formation of interparticle bridges. Resorption, or dissolution, of the hydroxyapatite particles is evident by this time period and appears to be associated with bone formation in the resorption cavities. The mechanism of the hydroxyapatite resorption is uncertain but may involve breakdown of grain boundaries in the sintered material, followed by fracture and bone formation along the fault lines.

3 Weeks After Implantation

Hard tissue sections of Bioglass particulate after 3 weeks show that much of the space between the particles is filled with trabecular bone. Decalcified sections illustrate the mature cellular nature of the new bone, which almost surrounds the glass particles. The integral nature of the particle bone architecture is especially clear in the back scattered scanning electron microscope image (Fig 4). All Bioglass particles in the peripheral layers (1 to 5) are bridged with new bone, and a substantial volume of previously open spaces is filled by bone. The reaction zone of some of the Bioglass particles extends almost throughout the particle.

By 3 weeks the center of the defect (layers 6–10) also is filled largely with new bone, which surrounds the Bioglass particulate. Nearly all particles are connected with thick bony bridges (Fig 4).

An energy dispersive spectroscopic analysis across a bone-Bioglass particle-bone bridge is shown in Figure 5. The line of the electron microscope beam trace is in the middle of the image. The intensity of Ca, P, and Si signals along this trace are coplotted in the figure. As expected, Ca and P have high concentrations in the bone on either side of the Bioglass particle. The electron dense, white reaction layer of the particle also is rich in Ca and P because of growth of the hydroxycarbonate apatite layer on the reactive glass surface, as described previously.[5,15,18] The interior of the Bioglass particle is Si rich because of the SiO_2 in the glass network.[5] The energy



Fig 4. The response to Bioglass after 3 weeks. Bar = 100 μm. Backscattered scanning electron microscope image showing new bone extending into the defect, surrounding and connecting the particles, which have a reaction layer greater than that seen at 1 week.

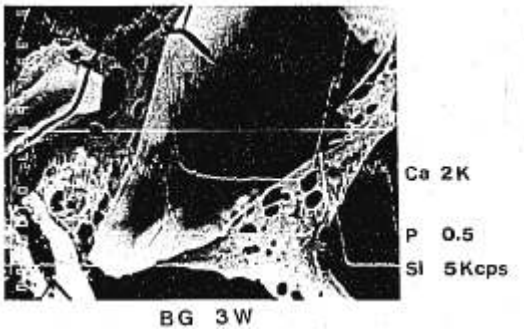

Fig 5. An energy dispersive spectroscopic analysis of the interface between a Bioglass particle encased in new bone at 3 weeks. The Ca and P intensities are high in bone. The Si intensity is high in the center of the particle and low in the interface and in bone.

dispersive spectrum of the Si concentration profile also shows Si within the interfacial boundary with bone, especially on the right side of the particle.

By 3 weeks new bone has formed bridges between a substantial fraction of the hydroxyapatite granules and has reached the center of the defect. Many hydroxyapatite particles in the periphery are surrounded by new bone. However, some hydroxyapatite particles are not incorporated within the trabecular architecture at 3 weeks. The distribution of bone is quite varied; some center portions have extensive bone, whereas others have almost no bone. Disintegration of the hydroxyapatite granules appears to be increasing. There is little correlation between hydroxyapatite degradation and bone growth.



Fig 6. The response to Bioglass after 6 weeks. Bar = 100 μm. Backscattered scanning electron microscope image of central area of the defect. Trabecular bone surrounds the particles in the central layers. The reaction layer on the particles is of a similar thickness to that observed at 3 weeks.

6 Weeks After Implantation

Figure 6 shows the tissue reaction to Bioglass particulate after 6 weeks of implantation. Bone growth between the glass particles continues to increase in density between 3 and 6 weeks. Thick, new trabecular bone completely encases the Bioglass particles. The distribution of the new bone throughout the 10 particle layers is nearly the same; there is little distinction between trabecular bone density in the center and the periphery.

However, the back scattered scanning electron microscope images of the 6-week Bioglass samples indicate that the density of bone between particles remains somewhat greater in the peripheral layers 1 to 5 than in the center of the hole. The small difference in bone density throughout the defect is almost entirely attributable to filling in of the interparticle spaces. Nearly all Bioglass particles are surrounded by bone, but the trabecular spaces are somewhat larger in the center. The intimate, contiguous nature of the bone particle interface is the same at the periphery as in the center. The reaction layer of the Bioglass particles also is about the same thickness throughout the defect, approximately ⅔ of the particle diameter.

Six weeks after implantation, new bone surrounds the hydroxyapatite granules in the outer 3 layers of the defect. In deeper layers (4 to 10) the new trabecular bone only partially surrounds the hydroxyapatite granules (Fig 7). Spaces between the particles are beginning to be filled in by new bone only within the first 2 layers in the periphery of the defect. The density of the interparticle bone remains fairly low, even in the periphery, because of limited growth along the surface of some of the hydroxyapatite particles.

In the center of the hole most, but not all, of the hydroxyapatite particles have new bone bridges between the granules (Fig 7). Where the particles are in close proximity, bone bridges bond the granules together. However, in areas where the granules are separated by several micrometers, there are few bone bridges. Little of the space between the hydroxyapatite granules is filled by bone in the center of the defect. Bone is present on some granules but has not proliferated far along the surface. Many granules have degraded because of dissolution of pores and have broken into smaller particles with bone filling in the pores (arrow) and intragranular spaces (Fig 7).



Fig 7. The response to hydroxyapatite after 6 weeks. Bar = 100 μm. Backscattered scanning electron microscope image of central area of the defect. Most hydroxyapatite particles at the center have a small layer of bone at their surface but are rarely surrounded by bone. Resorption areas within the particles contain new bone (arrow).

12 Weeks After Implantation

The back scattered scanning electron microscope images after 12 weeks of implantation of Bioglass particulate show a trabecular bone structure similar to that at 4 to 6 weeks. All glass particles are connected by bone



Fig 8. The reaction to Bioglass after 12 weeks. Bar = 100 μm. Backscattered scanning electron microscope image of peripheral area of the defect. The Bioglass particles are surrounded and encased in trabecular bone. The reaction layer extends throughout most particles (white areas). Some residual silica rich cores of particles (arrows) are present.

bridges throughout all 10 layers, from the periphery to the center of the defect. New bone encases the Bioglass particles and fills much of the interparticle space. The Ca, P rich reaction layer extends throughout most of the Bioglass particles, seen as white areas, with only the largest of the particles still retaining a Si rich core in the center (Fig 8, arrows).

By 12 weeks, new bone is present at the surface of most of the hydroxyapatite granules throughout the defect (Fig 9). Bone surrounds and encases many of the granules to a depth of 6 to 7 layers. Bone bridges have formed between most granules, even in the center of the hole. However, some areas in the center contain numerous hydroxyapatite particles that have little bone at their surface. The overall density of bone is about the same as at 6 weeks. Throughout the defect, the hydroxyapatite granules exhibit dissolution cavities, as noted at earlier times, with bone growth occurring within the intragranular pores. A trabecular architecture is being developed at 12 weeks, but there are many narrow contact points in the network.

The distance of bone growth into the approximately 10 layers of Bioglass and hydroxyapatite particles, as measured from the back scattered scanning electron microscope images, is summarized in Table 1 for the various postoperative times. The time required for Bioglass and hydroxyapatite particles within a layer (1–10 layers) to become surrounded by new bone also is compared in Table 1. Figure 10 compares the time dependence of the distance of bone growth for the



Fig 9. The reaction to hydroxyapatite after 12 weeks. Bar = 100 μm. Backscattered scanning electron microscope image of central area of the defect. Many particles are surrounded by bone, but the layer of bone often is thin (arrow).

TABLE 1. Bone Growth Around Particulates

	Layer			
	Bioglass		*Hydroxyapatite*	
Time	*Distance of Bone Growth*	*Large Portion Surrounded*	*Distance of Bone Growth*	*Large Portion Surrounded*
2 days	0.5	0.0	0.0	0.0
5 days	1–2	0.0	0.0	0.0
1 week	4	1	0.0	0.0
2 weeks	10	3–4	5	1
3 weeks	10	4–5	10	2
6 weeks	10	10	10	3
12 weeks	10	10	10	6–7

2 materials. The time required for bone to surround the greater part of particles within a layer also is shown.

Comparing the data in Table 1 and Figure 10 for the 2 materials shows a dramatic difference between Bioglass and hydroxyapatite particles. Within 1 week new bone has formed nearly halfway through the defect when the hole is filled with Bioglass particles, whereas there is little evidence of new bone formation within the array of hydroxyapatite particles at 1 week. By 2 weeks, new bone is found throughout the assemblage of Bioglass particles, even to the center of the defect; bone bridges between the particles are complete; and a trabecular network has been established. Longer times (6 and 12 weeks) continue to add bone to the bridges between Bioglass particles and continue to fill the interparticular spaces.

In contrast, 3 weeks is required for bone to proliferate throughout the array of hydroxyapatite granules (Fig 10), and even then bone is sparse in some portions of the center layers. Bone bridges have formed between numerous hydroxyapatite particles by 6 weeks, but even some granules in close proximity are not connected. There is little bone in the intergranular spaces, and the trabecular network is not apparent for hydroxyapatite even by 6 weeks. At 12 weeks, the situation for hydroxyapatite particles is essentially unchanged: bone conduction occurs along particles almost to the center of the defect, and some bony bridges are formed between particles. However, few hydroxyapatite granules are encased in bone, and there is little bone in the spaces between granules.

DISCUSSION

Previous clinical studies[9,11] have shown that hydroxyapatite granules can be used with

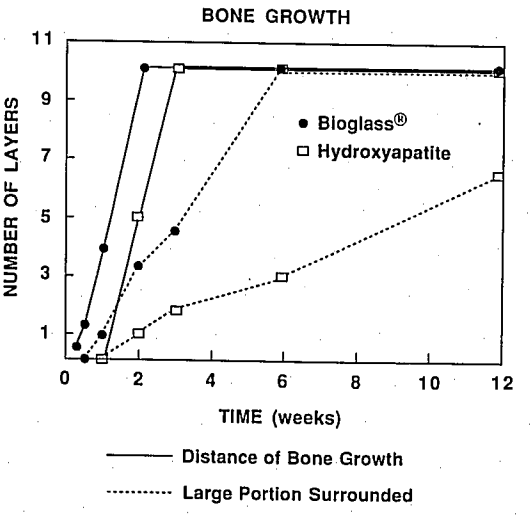

Fig 10. Comparison of the distance of bone growth into the femoral defect filled with Bioglass and hydroxyapatite particles and comparison of the extent of particles surrounded by bone as a function of time.

and without autograft bone chips to fill large bone defects after resection of bone tumors, for grafting of massive pelvic bone defects after loosening of total hip prostheses, for onlay grafting of the femur in revision surgery, and hydroxyapatite particles also can be interposed between bone and polymethylmethacrylate cement in total hip arthroplasty.

Clinical success has been reported for more than 300 cases during a 20-year followup.[9,11] The advantages of using hydroxyapatite are: (1) immunoreaction can be ignored; (2) postoperative morphologic changes and volume decreases do not occur if small blocks and chips are adequately packed during surgery; (3) postoperative absorption of hydroxyapatite, if any, is slight and slow and is replaced with bone; and (4) cement fixation performed on a layer of hydroxyapatite particles prevents the harmful influence of polyethylene wear particles on cement interfaces. The clinical disadvantages of hydroxyapatite particles are that they tend not to stay in place in a bleeding site, and there is a relatively slow restoration of bone within the assemblage of particles.

Results from the current study suggest that Bioglass particles may reduce both of these disadvantages of hydroxyapatite while retaining the advantages. When the Bioglass particles are mixed with saline or blood they rapidly form a cohesive mass because of the gel layer that forms on the surface in contact with moisture. Consequently, the particles pack into a defect easily and stay in place, even when the site is bleeding, as described for surgically created periodontal defects.[18] Clinical experience in periodontal surgery is widespread, and the hemostasis associated with the material continues to be seen.[15]

The data summarized in Figure 10 and Table 1 show that there is much more rapid proliferation of new bone within the Bioglass particulate array than occurs for the hydroxyapatite particles. This finding is consistent with earlier reports comparing Bioglass particulate with a variety of calcium phosphate ceramics in use in dentistry.[18,19] The rapid proliferation of bone in contact with Bioglass particles in the current model also confirms the findings of the experiment in canine rib augmentation, which demonstrated equivalent rates of bone growth for Bioglass particles and for autogenous bone graft. A mixture of Bioglass particles and autogenous bone resulted in substantially greater bone growth than did autogenous bone alone. This rapid rate of bone proliferation was proposed to be attributable to colonization of the surface of the Bioglass particles by bone stem cells that rapidly proliferated.[20] A similar phenomenon was observed in the 2- to 5-day time periods of this study. The osteoproduction at the surface of the Bioglass particles quickly spread through the entire particle assemblage, reaching the center by 2 weeks. Bone grew rapidly from this layer and quickly formed a mature trabecular structure throughout the defect. These results are consistent with clinical findings in the use of this material in maxillofacial repair.[15]

This osteogenic character of the Bioglass particulate array may be related to the activation of an autocrine mechanism in osteoblasts mediated by induction of transforming growth factor β secretion, as proposed by Keeting et al[7] to explain the mitogenic effects of zeolite A extract and soluble silicon on human osteoblast like cells in culture. Bioglass particulate releases a substantial concentration of soluble silicon, as well as soluble Ca and P, during the first few days in contact with body fluids, which may be responsible for the osteogenic effects observed in this study.[4,5]

However, it is important to recognize that the rabbit femoral model used provides a favorable environment for rapid healing of bone. Comparing the effect of Bioglass particulate and hydroxyapatite particulate with and without autogenous bone chips in a critical size defect in species other than rabbit would be desirable considering the potential clinical relevance of these findings.

CONCLUSIONS

This study shows that the reaction of bone to Bioglass particulate is more rapid than that to hydroxyapatite granules in a femoral defect in rabbit. An advantage of the particulate form of Bioglass appears to be that it becomes incorporated into the growing bone as its components are used up by the new bone. In animal experiments and in clinical biopsy specimens taken at various times after augmentation, it appears that most of the particulate has been used up by 8 to 12 weeks and cannot be identified at later times. The rate of bone proliferation depends on the species, the implant site, and the particle size. In the rabbit, femoral condyle bone repair may be completed with disappearance of the particulate at some time shortly after the 12-week interval studied. The repaired tissue will be bone, not a composite of bone reinforced by the alloplastic material, such as is seen with hydroxyapatite granules. The rapidity of the response and the eventual normal bone structure may overcome the clinical disadvantages associated with hydroxyapatite.

References

1. Brown KLB, Cruess RL: Bone and cartilage transplantation in orthopaedic surgery, a review. J Bone Joint Surg 64A:270–279, 1992.
2. Damien CJ, Parsons JR: Bone graft and bone graft substitutes: A review of current technology and applications. J Appl Biomater 2:187–208, 1991.
3. Habal MB, Reddi AH: Different Forms of Bone Grafts. In Habal MB, Reddi AH (eds). Bone Grafts and Bone Substitutes. Philadelphia, WB Saunders 6–8, 1992.
4. Hench LL: Bioceramics: From concept to clinic. J Am Ceram Soc 74:1487–1510, 1991.
5. Hench LL: Bioactive Ceramics: Theory and Clinical Applications. In Andersson ÖH, Happonen R-P, Yli-Urpo A (eds). Bioceramics 7. Oxford, Butterworth-Heinemann 3–16, 1994.
6. Jasty M, Mulroy Jr JD, Harris WH: Bone Grafting in Total Hip Replacement and Implant Interface. In Habal MB, Reddi AH (eds). Bone Grafts and Bone Substitutes. Philadelphia, WB Saunders 276–288, 1992.
7. Keeting PE, Oursler MJ, Weigand KE, et al: Zeolite A increases proliferation, differentiation, and transforming growth factor β production in normal adult human osteoblast-like cells in vitro. J Bone Miner Res 7:1281–1289, 1992.
8. Merwin GE: Bioglass® middle ear prosthesis: Preliminary report. Ann Otol Rhinol Laryngol 95:78–82, 1986.
9. Oonishi H: Orthopaedic applications of hydroxyapatite. Biomaterials 12:171–178, 1991.
10. Oonishi H: Development and Application of Bioceramics in Orthopaedic Surgery. In Muster D (ed). Biomaterials—Hard Tissue Repair and Replacement. Amsterdam, Elsevier 17–25, 1992.
11. Oonishi H, Tsuji E, Kushitani S, Aono M, Minami K: Bone Ingrowth Behavior Differences Into Spaces Between Fine Hydroxyapatite and Alumina Granules. In Yamamuro T, Kokubo T, Nakamura T (eds). Bioceramics 5. Kyoto, Kobonshi Kankokai 147–153, 1992.
12. Oonishi H, Tsuji E, Mizukoshi T, et al: The Replacing Behavior of Tetra-Calciumphosphate (TeCP)—Alteration to Bone Tissue In Vivo. In Bonfield W, Hastings GW, Tanner KE (eds). Bioceramics 4. Guildford, Butterworth-Heinemann 191–197, 1991.
13. Stanley HR, Hall MB, Colaizzi F, Clark AE: Residual alveolar ridge maintenance with a new endosseous implant material. J Pros Dent 58:607–613, 1987.
14. Urist MR, O'Connor BT, Burwell RG: Bone Grafts, Derivatives and Substitutes. Oxford, Butterworth-Heinemann 1994.
15. Wilson J, Clark AE, Douek E, et al: Clinical Applications of Bioglass® Implants. In Andersson ÖH, Happonen R-P, Yli-Urpo A (eds). Bioceramics 7. Oxford, Butterworth-Heinemann 415–422, 1994.
16. Wilson J, Clark AE, Hall MB, Hench LL: Tissue response to Bioglass® endosseous ridge maintenance implants. J Oral Implantology 19:295–302, 1993.
17. Wilson J, Douek E, Rust K: Bioglass® Middle Ear Devices: 10 Year Clinical Results. In Wilson J, Hench LL, Greenspan DC (eds). Bioceramics 8. Oxford, Pergamon 239–245, 1995.
18. Wilson J, Low S: Bioactive ceramics for periodontal treatment: comparative studies in the patus monkey. J Appl Biomater 3:123–129, 1992.
19. Wilson J, Low S, Fetner A, Hench LL: Bioactive Materials for Periodontal Treatment: A Comparative Study. In Pizzoferrato A, Marchetti, PG, Lee AJC (eds). Biomaterials and Clinical Applications. Amsterdam, Elsevier 223–228, 1987.
20. Wilson J, Yu LT, Beale BS: Bone Augmentation Using Bioglass® Particulates in Dogs: Pilot Study. In Yamamuro T, Kokubo T, Nakamura T (eds). Bioceramics 5. Kyoto, Kobonshi Kankokai 139–146, 1992.