# Revision surgical technique for laterally placed MinuteMan® interspinous devices using a novel VertiFix® removal system through a spinous process-preserving midline approach with InSpan fusion

**Sandra Thompson[1,2], Vito Lore[2,3], Erik Spayde[2,4], Taylor Headley[2], Jordan Acosta[1], Hope Estevez[2,5], Sukanya Chebrolu[2,5], Jason A Seale[2,5], Kingsley R. Chin[2,5,6,7]**

[1]The Pain Center Inc., Boise, ID, USA; [2]Less Exposure Spine Surgery (LESS) Society 501(c)(3), Fort Lauderdale, FL, USA; [3]LESSpine Innovations, Burlington, MA, USA; [4]St. Charles Spine Institute, Thousand Oaks, CA, USA; [5]Less Exposure Spine Surgery Institute (LESS Institute aka LESS Clinic), Fort Lauderdale, FL, USA; [6]Department of Orthopedics, Herbert Wertheim College of Medicine at Florida International University, Miami, FL, USA; [7]Faculty of Science and Sports, University of Technology, Kingston, Jamaica

*Contributions:* (I) Conception and design: S Thompson, KR Chin, E Spayde, V Lore, JA Seale; (II) Administrative support: J Acosta, H Estevez, S Chebrolu, T Headley; (III) Provision of study materials or patients: S Thompson, KR Chin, J Acosta; (IV) Collection and assembly of data: J Acosta, H Estevez, S Chebrolu, JA Seale; (V) Data analysis and interpretation: S Thompson, KR Chin, JA Seale, S Chebrolu; (VI) Manuscript writing: All authors; (VII) Final approval of manuscript: All authors.

*Correspondence to:* Kingsley R. Chin, MD, MBA. Less Exposure Spine Surgery (LESS) Society 501(c)(3), Fort Lauderdale, FL, USA; Professor of Clinical Orthopedics, Herbert Wertheim College of Medicine at Florida International University, FL, USA; Adjunct Professor, Faculty of Science and Sports, University of Technology, Kingston, Jamaica; Attending Spine Surgeon, Less Exposure Spine Surgery Institute (LESS Institute aka LESS Clinic), 6550 N Federal Hwy Suite #510, Fort Lauderdale, FL 33308, USA. Email: kingsleychin@thelessinstitute.com.

**Abstract:** The MinuteMan® interspinous fixation device (IFD) is a titanium implant designed for percutaneous lateral placement to provide interspinous distraction and stabilization in the treatment of lumbar spinal stenosis and interspinous fusion when combined with bone graft. With increasing use by interventional pain management physicians, standardized techniques for revision of failed lateral interspinous implants are needed. Revision is technically challenging due to dense scar tissue formation and limited access to the implant, particularly when preservation of the spinous processes is required to allow reinstrumentation. To our knowledge, there are no prior reports describing removal of a laterally placed IFD with revision using a midline interlaminar IFD. We describe a spinous process-preserving open midline surgical technique using the VertiFix® interspinous removal system for removal of a laterally placed IFD, followed by reinstrumentation with a midline interlaminar IFD (InSpan®) to facilitate interspinous fusion. The technique involves circumferential scar tissue release, controlled implant removal, decompression, and revision implant placement. Patients demonstrated 60% and 70% reductions in pain at three months. Revision was associated with implant size increases from 8 to 14 mm and 16 mm, with restoration of interspinous height. Postoperative imaging confirmed stable implant positioning without complications. This two-case technical report describes a feasible posterior midline revision approach for selected failed laterally placed IFDs. The technique may allow controlled implant removal and interspinous reinstrumentation when the posterior elements remain suitable; however, larger studies with longer follow-up and radiographic fusion assessment are needed to evaluate reproducibility, fusion, durability, and long-term clinical outcomes.

**Keywords:** Interspinous fixation; revision spine surgery; lumbar spinal stenosis; minimally invasive spine surgery (MISS); interlaminar fixation

Submitted Jun 02, 2026. Accepted for publication Jul 28, 2026. Published online Aug 31, 2026.

doi: 10.21037/jss-2026-0148

**View this article at:** https://dx.doi.org/10.21037/jss-2026-0148

© AME Publishing Company.

## Introduction

### *Background*

Lumbar spine surgery has evolved from traditional open procedures to minimally invasive techniques that reduce tissue disruption and accelerate recovery (1-5). Historically, conditions such as spinal stenosis, spondylolisthesis, and degenerative disc disease were treated with open decompression procedures, including laminectomy and fusion, following the initial description of lumbar disc herniation by Mixter and Barr (6). Although effective for neural decompression, these approaches required extensive muscle dissection and were associated with prolonged recovery, increased blood loss, and higher perioperative morbidity (7,8).

Advances in surgical techniques and imaging have enabled minimally invasive spine surgery (MISS) approaches that preserve normal anatomy while achieving adequate decompression and stabilization (1,3,5,9). These techniques have been associated with reduced operative morbidity, postoperative pain, and shorter hospital stays compared with traditional open procedures (4,7). Within this evolution, interspinous fixation and stabilization devices have emerged as alternative treatment strategies for selected lumbar degenerative conditions (10-13).

More recently, interventional pain management (IPM) physicians have incorporated minimally invasive spinal stabilization procedures into clinical practice, including percutaneous lumbar decompression and interspinous fixation techniques (14-16). This reflects a broader trend toward less invasive spine care across specialties.

Devices such as the MinuteMan® interspinous fixation device (IFD) (Spinal Simplicity LLC, Overland Park, KS) gained popularity because they allow stabilization of the interspinous space through a lateral percutaneous fluoroscopically guided approach in selected patients (10-12,17). The technique involves serial dilation through the multifidus musculature followed by placement of an implant that distracts the interspinous space and stabilizes the motion segment. This minimally invasive outpatient procedure may be suitable for patients who are not optimal candidates for more extensive open surgery.

### *Rationale*

Despite these advantages, important limitations of IFD placed laterally have been reported. The lateral approach limits direct access to key posterior bony structures, including the facets, lamina, and transverse processes which are critical for achieving robust osseous fusion. Consequently, fusion rates may be variable, and implant loosening or mechanical failure can occur in some patients (18,19). These complications may present clinically as recurrent pain, neurological symptoms, or spinal instability, often requiring revision surgery.

Revision of failed laterally placed interspinous devices presents distinct technical challenges. Loosening of these implants often results in exuberant scar tissue formation surrounding the implant and adjacent musculature. In the case of the MinuteMan® device, the lateral position of the locking nut further complicates removal, frequently necessitating increased muscle dissection and retraction. These factors increase procedural complexity and may contribute to increased surgical morbidity.

**Highlight box**

**Surgical highlights**

- Revision of laterally placed interspinous fixation devices is technically challenging due to dense scar tissue formation and limited implant access.
- A spinous process-preserving open midline technique using the VertiFix® system enables circumferential scar tissue release, controlled implant removal, decompression, and reinstrumentation.
- The technique allows conversion from a lateral to a midline interspinous fixation construct through a single approach.

**What is conventional and what is novel/modified?**

- Conventional interspinous fixation systems are typically placed via a midline approach, allowing direct visualization and preparation of the fusion bed.
- This study introduces a novel revision strategy that converts a laterally placed implant into a directly visualized posterior midline revision approach while preserving the spinous processes for reinstrumentation. Key technical elements include ligament release, implant resizing, and decortication of the lamina and facet joints with biologic graft augmentation.

**What is the implication, and what should change now?**

- Failed lateral interspinous implants should be assessed for whether spinous process-preserving revision and interspinous reinstrumentation remain feasible before selecting a more extensive revision strategy.

© AME Publishing Company.

- Revision planning should account for implant loosening or migration, persistent stenosis, segmental instability, and structural integrity of the spinous processes.
- Dedicated interspinous removal instrumentation may facilitate controlled removal of a laterally placed failed implant and support a more consistent posterior midline revision approach.

Midline interlaminar IFD such as the InSpan® interlaminar interspinous fixation device (LESSpine Innovations, Burlington, MA, USA) provide an alternative stabilization strategy that allows improved access to posterior spinal elements and facilitates interspinous fusion (20-22). This system uses a midline approach and incorporates bilateral locking set screws with a symmetrical plate design to enhance biomechanical stability (23). Midline placement also allows direct visualization and preparation of the interspinous space and adjacent bony structures, which may support improved fusion outcomes. In addition to implant design, advances in biologic graft materials, such as NanoFuse Biologics® (Amend Surgical Inc., Alachua, FL, USA), which combines bioactive glass with demineralized bone matrix, may enhance osteoconductivity and fusion potential when used with interspinous fixation systems (24,25).

Recent literature highlights the continued role of IFD in the treatment of lumbar degenerative conditions when appropriate patient selection and surgical technique are applied (20). However, standardized techniques for revision of failed lateral interspinous implants remain poorly described. To our knowledge, there are no prior reports describing removal of a laterally placed IFD with revision using a midline interlaminar IFD system.

### *Objective*

This study describes an open midline technique using a dedicated interspinous removal system for removal of a failed lateral IFD while preserving the spinous processes, enabling reinstrumentation with a midline interlaminar IFD for interspinous and posterolateral fusion with biologic graft augmentation. Two cases illustrate the technical feasibility and application of this revision approach. We present this article in accordance with the SUPER reporting checklist (available at https://jss.amegroups.com/article/view/10.21037/jss-2026-0148/rc).

## Preoperative preparations and requirements

Patients selected for this technique demonstrated symptomatic failure of a laterally placed IFD, defined as recurrent or worsening back and/or leg pain following an initial period of postoperative improvement. Both patients had failed at least six months of conservative management, including pharmacologic therapy and/or spinal injections. Revision was only considered when clinical symptoms correlated with imaging findings demonstrating implant-related complications, including loosening or migration (*Figure 1A*), persistent spinal stenosis, and preserved spinous process integrity adequate for reinstrumentation. Preoperative Visual Analog Scale (VAS) scores were obtained to assess baseline pain severity. Contraindications to this technique included active infection, severe segmental instability requiring pedicle screw fixation, or inadequate spinous process integrity precluding interspinous fixation.

All procedures were performed under general anesthesia with the patient in the prone position on a radiolucent operating table. Fluoroscopy was utilized intraoperatively. The surgical setup included the VertiFix® interspinous removal system (NANISX LLC, Fort Lauderdale, FL, USA), decompression instruments including a decompression knife, rongeur and broach, and the InSpan® IFD. All procedures

© AME Publishing Company.

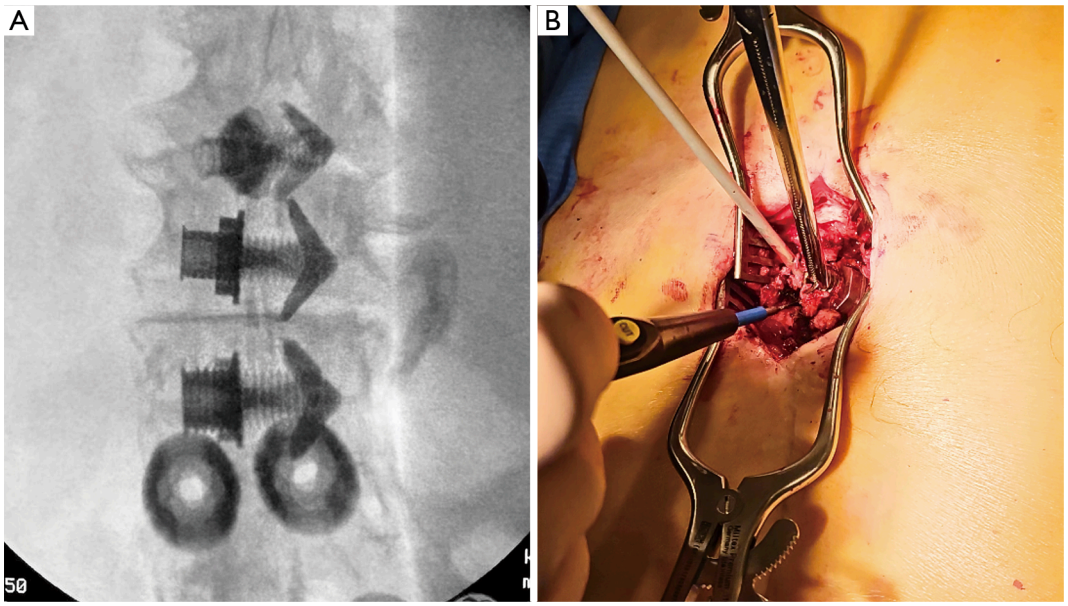


**Figure 1** Case 1. (A) Preoperative anteroposterior (AP) fluoroscopic view demonstrating a rotated laterally placed MinuteMan® interspinous fixation device at L1–2, angled within the interspace consistent with implant loosening. (B) Intraoperative view demonstrating removal of fibrous scar tissue and exposure of the lateral locking component of the MinuteMan® implant.

were performed by the primary author under the direct supervision of a board-certified orthopedic spine surgeon in an outpatient ambulatory surgery center. All procedures performed in this study were in accordance with the ethical standards of the Western Institutional Review Board (WIRB®) now known as WIRB-Copernicus Group (WCG® IRB) (WIRB#20181251) and with the Declaration of Helsinki and its subsequent amendments. Written informed consent was obtained from all individual participants for the publication of this study, accompanying images and the video. A copy of the written consent is available for review by the editorial office of this journal.

## Step-by-step description

### *Surgical technique*

The posterior midline approach was selected to provide direct visualization of the implant and posterior elements while preserving the spinous processes for reinstrumentation.

### *Exposure*

The procedure was performed using an open midline posterior approach. Under fluoroscopic guidance, a midline incision was made over the affected level and carried through the lumbodorsal fascia to expose the spinous processes. Subperiosteal dissection was performed using electrocautery to expose the posterior elements, including the spinous processes and lamina, while preserving the surrounding paraspinal musculature and ligamentous structures.

© AME Publishing Company.

### *Scar tissue removal and implant exposure*

Following exposure, scar tissue and adherent multifidus muscle fibers surrounding the implant were carefully released (*Figure 1B*). The implant was palpated along the lateral border, and a cephalocaudal sweep was performed to establish a plane between the implant and surrounding musculature. The VertiFix® decompression knife was then advanced ventral and dorsal to the implant to achieve circumferential release of scar tissue. A Leksell rongeur was subsequently used to remove residual fibrous tissue from the superior and lateral surfaces of the implant, facilitating exposure of the lateral locking nut. This stepwise dissection enabled progressive mobilization of the implant while preserving the integrity of the spinous processes.

### *Implant removal*

After complete circumferential release of the surrounding scar tissue and residual adhesions using dedicated instruments from the VertiFix® interspinous removal system, the implant was mobilized and extracted through controlled, sequential mobilization (*Figure 2*, *Video 1*). Electrocautery was used selectively as needed while maintaining protection of adjacent soft tissues and neural elements. Care was taken to avoid levering against the cephalad or caudal spinous processes or applying excessive force, which could result in spinous process fracture. No gross osseous erosion of the superior or inferior spinous processes was observed intraoperatively, and structural integrity was maintained despite mild surface changes. Preservation of the spinous processes was prioritized to allow subsequent placement of a replacement IFD.

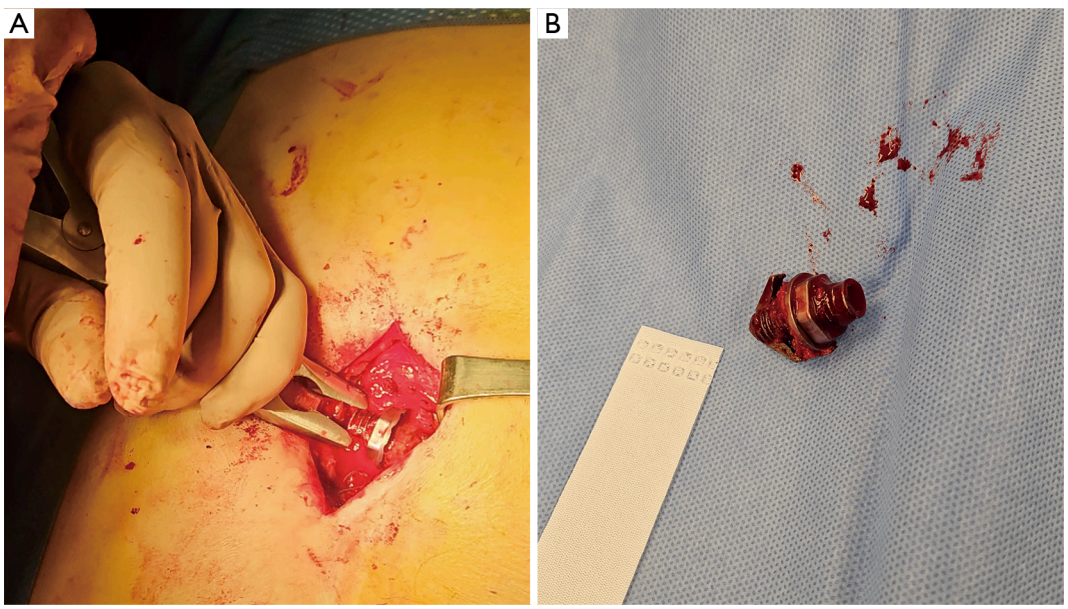


**Figure 2** Case 1. Intraoperative photo of the removed MinuteMan® implant.

© AME Publishing Company.



**Video 1** Intraoperative video showing removal of the MinuteMan® interspinous fixation device through a midline approach. The accompanying operative video contains no patient-identifying information.

### *Decompression and fusion bed preparation*

Midline decompression was performed with resection of the posterior ligamentum flavum to achieve neural decompression (*Figure 3A*). The interspinous space was then distracted using a sizing instrument under fluoroscopic guidance to determine the appropriate InSpan implant size and restore interspinous height. Decortication of the spinous processes was performed to prepare the interspinous fusion bed (*Figure 3B*).

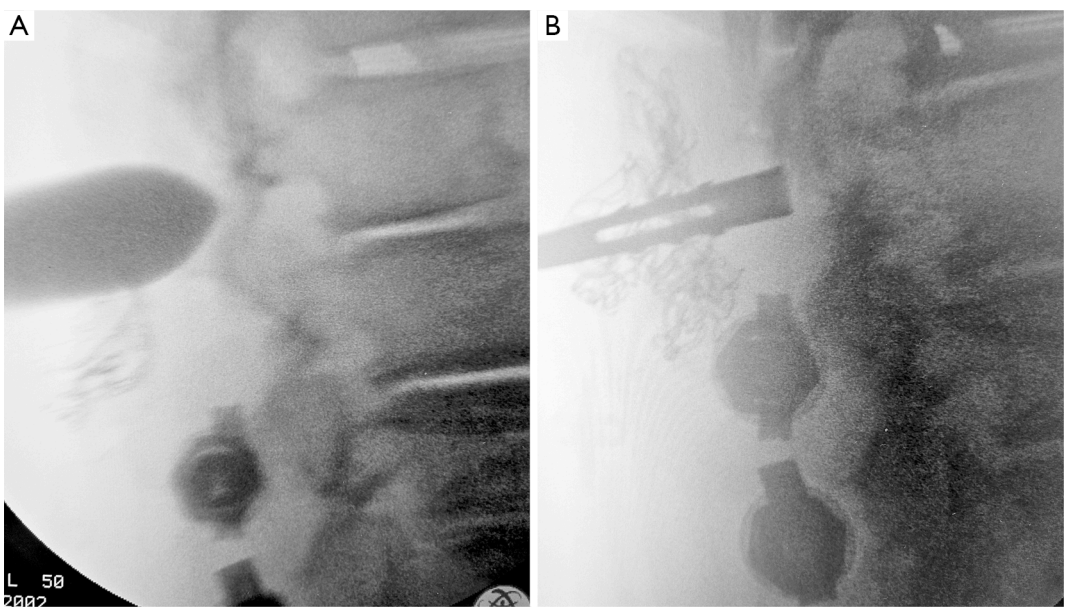


**Figure 3** Case 1. Fluoroscopic lateral views of the VertiFix® interspinous removal system. (A) Decompression knife positioned between spinous process and multifidus muscle. (B) Broach positioned between the spinous processes following advancement through residual scar tissue and interspinous ligaments, preparing the interspinous fusion bed for bone graft.

© AME Publishing Company.

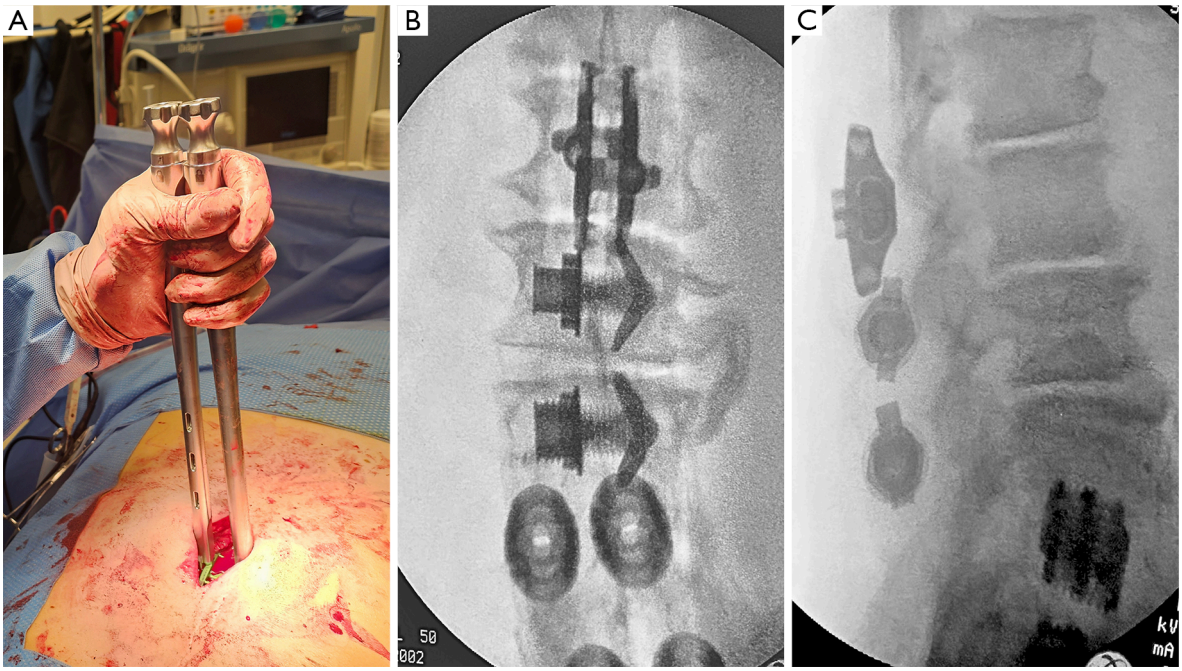


**Figure 4** Case 1. (A) Intraoperative photograph showing insertion of the InSpan® interlaminar-interspinous fixation device. Fluoroscopic (B) anteroposterior (AP) and (C) lateral views demonstrating final implant positioning and restoration of interspinous height at L1–2.

### *InSpan implant placement*

The InSpan IFD was prepared by packing with autograft and NanoFuse Biologics into the implant hub. The device was inserted between the spinous processes and advanced under fluoroscopic guidance until seated anteriorly between the laminae (*Figure 4*). The implant was compressed against the spinous processes and secured using bilateral locking set screws. A pull-up test was performed to confirm stable fixation of the implant (20). The dorsal surfaces of the facet joints were decorticated bilaterally with the broach (*Figure 5*). Autograft mixed with synthetic biologic graft material was placed above the implant hub and posterolaterally over the decorticated lamina and facet joints to promote fusion.

### *Wound closure and postoperative care*

The surgical site was irrigated with antibiotic solution prior to closure. Layered wound closure was performed including fascia, subcutaneous tissue, and skin. A sterile dressing was applied.

## Postoperative considerations and tasks

Postoperatively, patients were monitored for neurologic status, wound healing, and implant-related complications. Follow-up radiographs were obtained to assess implant positioning and interspinous distraction. Patients were followed clinically and VAS was collected at three months postoperatively.

© AME Publishing Company.

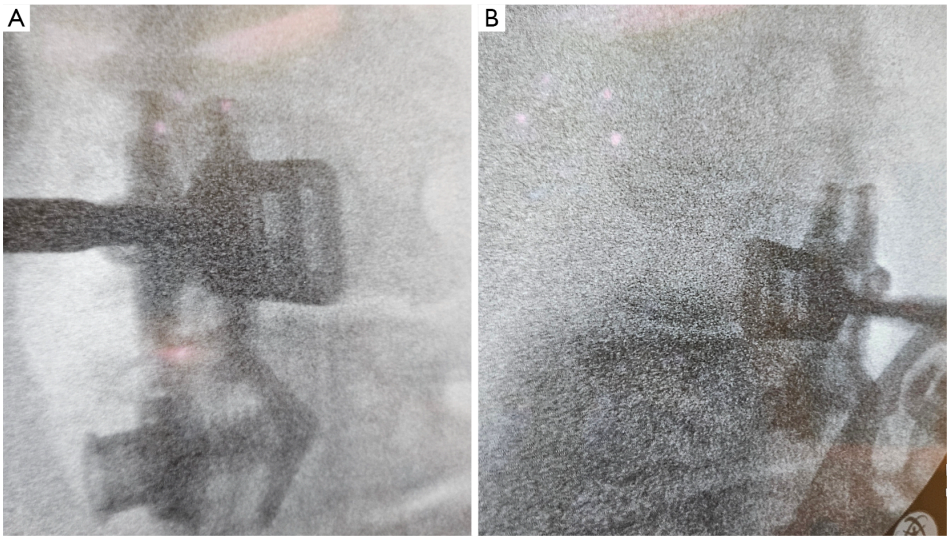


**Figure 5** Case 1. Oblique fluoroscopic views (A,B) demonstrating bilateral facet joint decortication with the broach.

## Tips and pearls

Successful execution of this technique depends on thorough scar tissue release to achieve adequate implant mobilization. This step is critical for controlled extraction and facilitates identification, exposure and release of the lateral locking mechanism. Careful finger dissection along the lateral border of the implant can assist in confirming separation from surrounding musculature and establishing a safe working plane. Care should be taken to avoid excessive force during implant extraction, as this may result in spinous process fracture. Over-resection of posterior elements should likewise be avoided, as this may destabilize the spinal segment and necessitate more extensive posterior instrumentation or fusion.

The midline approach provides direct access to the spinous processes and facilitates their preservation, which is essential for placement of a replacement IFD. Preparation of the interspinous fusion bed, including decortication of the lamina and facet joints with placement of biologic graft material, may enhance the likelihood of successful arthrodesis.

Revision cases may require placement of larger interspinous implants compared with the primary procedure, likely due to prior undersizing and incomplete distraction. Consideration should also be given to the potential need for larger implant hub sizes in revision settings, particularly when spinous processes are enlarged or altered by scar tissue.

## Results

Patient demographics and surgical characteristics are summarized in *Table 1*. Both patients demonstrated postoperative improvement in pain following revision surgery. Preoperative VAS pain scores were 10/10 in both cases. At 3-month follow-up, VAS scores improved to 4/10 and 3/10, representing 60% and 70% reductions in pain, respectively.

© AME Publishing Company.

**Table 1** Patient demographics and surgical characteristics

| Characteristics | Case 1 | Case 2 |
|---|---|---|
| Sex | Male | Male |
| Age (years) | 74 | 50 |
| BMI (kg/m$^2$) | 30 | 23 |
| Level | L1–2 | L5–S1 |
| Original implant (MinuteMan®) | 8 mm | 8 mm |
| Revision implant (InSpan®) | 14 mm | 16 mm |
| Operative time (min) | 123 | 89 |
| EBL (cc) | <50 | <50 |
| Preoperative VAS | 10 | 10 |
| VAS at 3 months | 4 | 3 |
| VAS change | 60% | 70% |

BMI, body mass index; EBL, estimated blood loss; VAS, Visual Analog Scale.

Intraoperatively, the lateral interspinous implants were found to be loosened and encased in fibrous scar tissue, with mild surface erosion of the spinous processes without compromise of structural integrity. Complete scar tissue clearance and implant removal were performed using the VertiFix® interspinous removal system, with preservation of the spinous processes in both cases. Estimated blood loss was less than 50 cc in each case. Operative times were 123 and 89 minutes for the L1–2 and L5–S1 revisions, respectively. Both patients were discharged home the same day.

The original implants (8 mm) were replaced with larger devices (14 mm at L1–2 and 16 mm at L5–S1), representing increases in implant height of 75% and 100%, respectively. Restoration of interspinous distraction was achieved in both cases.

Final fluoroscopic and postoperative imaging demonstrated stable positioning of the revision InSpan IFD without evidence of migration, malposition, or hardware-related complications (*Figure 6*).

No intraoperative or postoperative complications were observed, including excessive bleeding, neurologic injury, infection, wound complications, or implant failure.

## Discussion

### *Surgical highlights*

Revision of failed lateral IFD presents significant technical challenges related to implant design, scar tissue formation, and limited surgical access. In this study, we describe a novel open midline technique using the VertiFix® system for removal of a laterally placed MinuteMan® IFD while preserving the spinous processes, enabling reinstrumentation with a midline IFD (InSpan®).

In both cases, the technique allowed circumferential scar tissue release and controlled implant removal with preservation of the posterior elements. Patients demonstrated early improvement in pain, with VAS reductions of 60% and 70% at three months.

© AME Publishing Company.

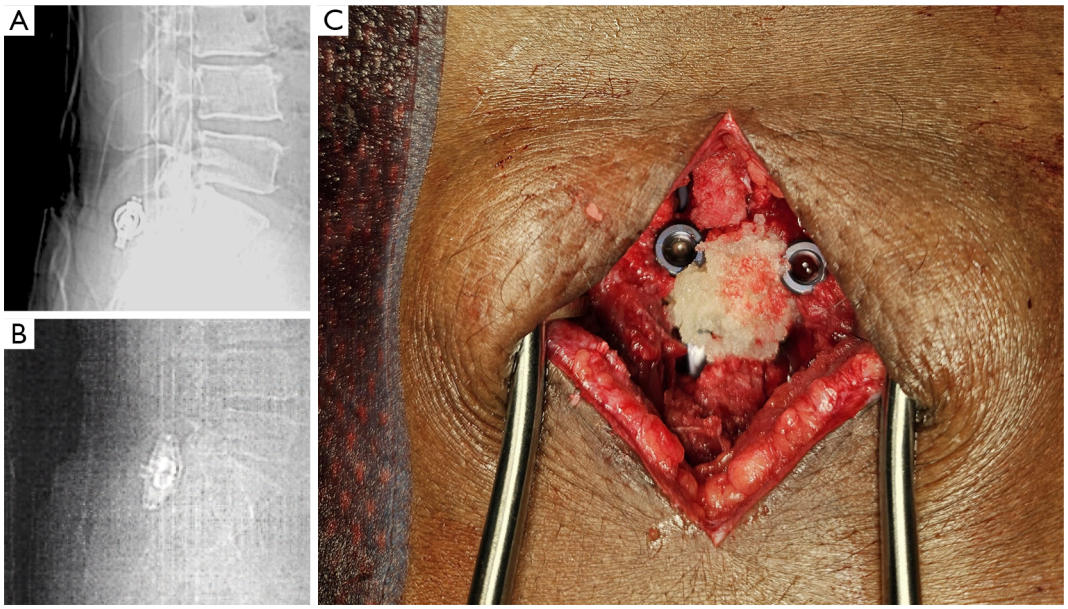


**Figure 6** Case 2. (A) Preoperative lateral radiograph of a MinuteMan® implant at L5–S1. (B) Postoperative lateral radiograph of reinstrumentation with an InSpan® interlaminar-interspinous fixation device at L5–S1. (C) Intraoperative photo of InSpan® device.

Radiographic evaluation confirmed stable implant positioning and restoration of interspinous distraction without complications.

A potential key technical advantage of this approach is preservation of the spinous processes, which may help maintain posterior structural integrity and allow placement of a larger replacement implant in selected patients without requiring additional posterior instrumentation. The ability to perform decompression, stabilization, and fusion through a single midline approach may be useful in selected reveision cases when the posterior elements remain suitable for reinstrumentation. These technical objectives are consistent with the principles of Less Exposure Spine Surgery (LESS™), including direct visualization, limited soft-tissue disruption, and preservation of native posterior spinal anatomy.

### *Strengths and limitations*

The primary strength of this study is the description of a stepwise surgical technique for revision of laterally placed IFDs, an area that remains poorly described in the literature. The use of VertiFix® dedicated instrumentation facilitated controlled implant removal with the goal of limiting disruption to surrounding tissues and preserving the spinous processes for reinstrumentation.

However, several limitations should be acknowledged. This report includes only two patients treated by a single physician under the supervision of a board-certified orthopedic spine surgeon, which may limit generalizability and reproducibility across different practice settings. Follow-up was limited to three months; therefore, long-term durability, recurrent symptoms, and successful arthrodesis could not be assessed. Radiographic fusion assessment and functional outcome measures such as Oswestry

© AME Publishing Company.

Disability Index were not available. Finally, this report does not compare the described approach with alternative revision strategies, including implant removal alone, decompression without reinstrumentation, posterolateral fusion, or pedicle screw-based fixation.

Future studies involving larger patient cohorts, multiple surgeons, standardized functional outcome measures, radiographic fusion assessment, comparison groups, and longer follow-up periods will be necessary to further evaluate reproducibility, durability, safety, fusion, and long-term clinical effectiveness.

### *Comparison with other surgical techniques and research*

Interspinous fixation systems have been increasingly utilized as an alternative to traditional pedicle screw-based fusion in selected patients with lumbar degenerative disease (10-13,19). Several studies have demonstrated favorable clinical outcomes with interspinous fixation when combined with decompression and appropriate patient selection (20-22,26,27).

Recent comparative studies have suggested that interspinous fixation may achieve similar clinical outcomes to more invasive fusion procedures while reducing operative morbidity. These techniques have also been adopted by IPM physicians performing minimally invasive spine procedures in ambulatory surgery centers (14,15).

Most interspinous fixation systems described in the literature utilize a midline approach for implantation (28). In contrast, the MinuteMan® device is uniquely designed for lateral percutaneous placement through the multifidus musculature (8,12,17). From a revision-planning perspective, lateral and midline interspinous fixation approaches differ in exposure, implant access, and access to the posterior elements. In this report, these differences are presented as technical considerations rather than evidence of clinical superiority of one approach over another.

While this approach offers a minimally invasive alternative, it preserves the interspinous and supraspinous ligaments, which may limit the ability to achieve adequate interspinous distraction and optimal implant sizing. In the present cases, revision to a midline interspinous fixation system following ligament release allowed for substantially increased implant sizing, suggesting that preservation of the posterior ligamentous complex during lateral implantation may contribute to undersizing and incomplete distraction.

Device failure and nonunion remain recognized complications of interspinous fixation systems (18,19). Despite this, there is limited literature describing revision techniques, particularly for laterally placed devices. The present study contributes to the literature by describing a midline revision approach that allows controlled removal of a lateral implant while preserving the spinous processes for replacement fixation.

### *Implications and actions recommended*

The technique described in this study has several important clinical implications. First, it provides a stepwise method for removal of laterally placed IFDs while preserving the posterior elements, which is critical for enabling reinstrumentation with another interspinous device. Alternative revision strategies may include implant removal alone, decompression without reinstrumentation, conversion to pedicle screw-based posterior

© AME Publishing Company.

fusion, or decompression with posterolateral fusion, depending on the degree of stenosis, instability, bone quality, sagittal alignment, and integrity of the spinous processes. The technique described in this report represents one revision option for selected patients in whom the spinous processes remain structurally adequate for reinstrumentation and should not be interpreted as the preferred approach for all failed interspinous implants.

Second, the midline approach allows direct visualization of the posterior spinal anatomy, facilitating decompression, preparation of the fusion bed, and placement of biologic graft material while minimizing disruption to surrounding tissues. In addition, appropriate biologic augmentation may play an important role in achieving successful fusion in interspinous fixation procedures. In the cases presented, absence of bone graft at the index procedure may have contributed to implant loosening and failure. The use of biologic materials, including bioactive glass combined with demineralized bone matrix, may enhance osteoconductivity and support arthrodesis when combined with adequate fusion bed preparation (24). These cases highlight the need to consider graft placement and fusion bed preparation when attempting to achieve arthrodesis.

Removal of the interspinous and supraspinous ligaments during the revision procedure may allow greater interspinous distraction and improved implant seating; however, whether this translates into improved stability, fusion, or clinical outcomes requires further study.

As the use of IFDs continues to expand across specialties, the development of standardized revision techniques will become increasingly important. Dedicated instrumentation, such as the VertiFix® system, may facilitate a more controlled revision workflow, although safety and reproducibility will require evaluation in larger cohorts with longer follow-up.

## Conclusions

This report describes a spinous process-preserving open midline technique using VertiFix® instruments for removal of a laterally placed MinuteMan® IFD, followed by reinstrumentation with an InSpan interspinous fixation device. In two revision cases, the technique permitted controlled scar tissue release, implant removal, decompression, and replacement fixation while preserving the spinous processes. Early postoperative findings demonstrate improved VAS pain scores and stable implant positioning at 3 months, without perioperative complications. As the use of IFD continues to expand, the development of standardized revision techniques will become increasingly important. Further studies with larger patient cohorts, radiographic fusion assessment and longer follow-up are needed to evaluate the effectiveness, reproducibility, and broader clinical applicability of this technique.

## Acknowledgments

None.

© AME Publishing Company. 

## Footnote

*Reporting Checklist:* The authors have completed the SUPER reporting checklist. Available at https://jss.amegroups.com/article/view/10.21037/jss-2026-0148/rc

*Peer Review File:* Available at https://jss.amegroups.com/article/view/10.21037/jss-2026-0148/prf

*Funding:* None.

*Conflicts of Interest:* All authors have completed the ICMJE uniform disclosure form (available at https://jss.amegroups.com/article/view/10.21037/jss-2026-0148/coif). K.R.C. serves as Chief Executive Office of KIC Ventures and is paid a fixed salary. K.R.C., S.T. and E.S. hold ownership interests in KIC Ventures. E.S. serves on the medical advisory board of KIC Ventures. K.R.C. and S.T. serve on the advisory board of directors of KIC Ventures. KIC Ventures holds ownership interests in LESSpine Innovations products. V.L. is an employee of LESSpine Innovations, a for-profit medical device company. The other authors have no conflicts of interest to declare.

*Ethical Statement:* The authors are accountable for all aspects of the work in ensuring that questions related to the accuracy or integrity of any part of the work are appropriately investigated and resolved. All procedures performed in this study were in accordance with the ethical standards of the Western Institutional Review Board (WIRB®) now known as WIRB-Copernicus Group (WCG® IRB) (WIRB#20181251) and with the Declaration of Helsinki and its subsequent amendments. Written informed consent was obtained from all individual participants for the publication of this study, accompanying images and the video. A copy of the written consent is available for review by the editorial office of this journal.

*Open Access Statement:* This is an Open Access article distributed in accordance with the Creative Commons Attribution-NonCommercial-NoDerivs 4.0 International License (CC BY-NC-ND 4.0), which permits the non-commercial replication and distribution of the article with the strict proviso that no changes or edits are made and the original work is properly cited (including links to both the formal publication through the relevant DOI and the license). See: https://creativecommons.org/licenses/by-nc-nd/4.0/.

## References

1. Oppenheimer JH, DeCastro I, McDonnell DE. Minimally invasive spine technology and minimally invasive spine surgery: a historical review. Neurosurg Focus 2009;27:E9.
2. Lurie J, Tomkins-Lane C. Management of lumbar spinal stenosis. BMJ 2016;352:h6234.
3. Momin AA, Steinmetz MP. Evolution of Minimally Invasive Lumbar Spine Surgery. World Neurosurg 2020;140:622-6.

4. Mobbs RJ, Sivabalan P, Li J. Minimally invasive surgery compared to open spinal fusion for the treatment of degenerative lumbar spine pathologies. J Clin Neurosci 2012;19:829-35.
5. Snyder LA, O'Toole J, Eichholz KM, et al. The technological development of minimally invasive spine surgery. Biomed Res Int 2014;2014:293582.
6. Mixter WJ, Barr JS. Rupture of the Intervertebral Disc with Involvement of the Spinal Canal. Journal of Neurosurgery 1964;21:74-81.
7. Patel AA, Zfass-Mendez M, Lebwohl NH, et al. Minimally Invasive Versus Open Lumbar Fusion: A Comparison of Blood Loss, Surgical Complications, and Hospital Course. Iowa Orthop J 2015;35:130-4.
8. Baranidharan G, Bretherton B, Feltbower RG, et al. 24-Month Outcomes of Indirect Decompression Using a Minimally Invasive Interspinous Fixation Device versus Standard Open Direct Decompression for Lumbar Spinal Stenosis: A Prospective Comparison. J Pain Res 2024;17:2079-97.
9. Fayssoux RS, Kim CW. Minimally invasive decompression. Seminars in Spine Surgery 2013;25:146-53.
10. Kaye AD, Edinoff AN, Temple SN, et al. A Comprehensive Review of Novel Interventional Techniques for Chronic Pain: Spinal Stenosis and Degenerative Disc Disease-MILD Percutaneous Image Guided Lumbar Decompression, Vertiflex Interspinous Spacer, MinuteMan G3 Interspinous-Interlaminar Fusion. Adv Ther 2021;38:4628-45.
11. Onggo JR, Nambiar M, Maingard JT, et al. The use of minimally invasive interspinous process devices for the treatment of lumbar canal stenosis: a narrative literature review. J Spine Surg 2021;7:394-412.
12. Skoblar M, Hedman T, Rogers AJ, et al. Instrumented Posterior Arthrodesis of the Lumbar Spine: Prospective Study Evaluating Fusion Outcomes in Patients Receiving an Interspinous Fixation Device for the Treatment of Degenerative Spine Diseases. J Pain Res 2023;16:2909-18.
13. Orlando V, Galieri G, Mazzucchi E, et al. Comparative Analysis of Pedicle Screw Fixation and Interspinous Devices in Lumbar Spinal Fusion: Clinical and Surgical Outcomes in Degenerative Spine Conditions. J Pers Med 2025;15:95.
14. Shah A, Hagedorn JM, Latif U, et al. Posterior Lateral Arthrodesis as a Treatment Option for Lumbar Spinal Stenosis: Safety and Early Clinical Outcomes. J Pain Res 2024;17:107-16.
15. Sarikonda A, Leibold A, Sivaganesan A. When Does Intervention End and Surgery Begin? The Role of Interventional Pain Management in the Treatment of Spine Pathology. Curr Pain Headache Rep 2023;27:707-17.
16. Giraldo JP, Williams GP, Dholaria N, et al. Prevalence of interventional spine procedures performed by pain management physicians: blurred boundaries. J Neurosurg Spine 2026;45:152-9.
17. Soto E, Esposito MF. Safety and Efficacy of Interspinous Fixation Device via Lateral Transverse Approach in Patients with Lumbar Spinal Stenosis: A Single Center, Retrospective, Observational Study. J Pain Res 2025;18:4431-41.
18. Tamburrelli FC, Proietti L, Logroscino CA. Critical analysis of lumbar interspinous devices failures: a retrospective study. Eur Spine J 2011;20 Suppl 1:S27-35.

© AME Publishing Company. 

19. Gazzeri R, Galarza M, Neroni M, et al. Failure rates and complications of interspinous process decompression devices: a European multicenter study. Neurosurg Focus 2015;39:E14.
20. Cahueque M, Azmitia E, Guerra M, et al. The renewed role of interspinous devices: the InSpan system-a narrative review on surgical indications. J Spine Surg 2026;12:37.
21. Chin KR, Seale JA, Spayde E, et al. Prospective 5-year follow-up of L5-S1 versus L4-5 midline decompression and interspinous-interlaminar fixation as a stand-alone treatment for spinal stenosis compared with laminectomies. J Spine Surg 2023;9:398-408.
22. Chin KR, Pencle FJR, Benny A, et al. Greater than 5-year follow-up of outpatient L4-L5 lumbar interspinous fixation for degenerative spinal stenosis using the INSPAN device. J Spine Surg 2020;6:549-54.
23. Chin KR, Lore V, Spayde E, et al. Advancing the design of interspinous fixation devices for improved biomechanical performance: dual vs. single-locking set screw mechanisms and symmetrical vs. asymmetrical plate designs. J Spine Surg 2024;10:386-94.
24. Kirk JF, Ritter G, Waters C, et al. Osteoconductivity and osteoinductivity of NanoFUSE(®) DBM. Cell Tissue Bank 2013;14:33-44.
25. Chin KR, Ilogu CC, Chebrolu S, et al. Comparative Osteoinductive Potential of BMP-2, Bioactive Glass, and Demineralized Bone Matrix: An In Vitro Alkaline Phosphatase Assay Study. Int J Spine Surg 2025;19:652-8.
26. Raikar SV, Patil AA, Pandey DK, et al. Inter Spinal Fixation and Stabilization Device for Lumbar Radiculopathy and Back Pain. Cureus 2021;13:e19956.
27. Ma J, Li T, Shen N, et al. Interspinous process fixation versus posterior lumbar interbody fusion following decompression for single-level grade I degenerative spondylolisthesis: a retrospective propensity score-matched study. J Orthop Surg Res 2026;21:159.
28. Mangal H, Felzensztein Recher D, Shafafy R, et al. Effectiveness of Interspinous Process Devices in Managing Adjacent Segment Degeneration Following Lumbar Spinal Fusion: A Systematic Review and Meta-Analysis. J Clin Med 2024;13:5160.

**Cite this article as:** Thompson S, Lore V, Spayde E, Headley T, Acosta J, Estevez H, Chebrolu S, Seale JA, Chin KR. Revision surgical technique for laterally placed MinuteMan® interspinous devices using a novel VertiFix® removal system through a spinous process-preserving midline approach with InSpan fusion. J Spine Surg 2026;12(9):149. doi: 10.21037/jss-2026-0148

© AME Publishing Company.